

Rotator Cuff Injuries: Is Ultrasound Enough? A Correlation with MRI

VISHAL DHIRENBHAI THAKKER, DIPU BHUYAN, MANALI ARORA, MOHSINA ISLAM BORA

ABSTRACT

Introduction: Shoulder pain is one of the most common presentations in Orthopaedic patients. Rotator cuff pathologies consist of a significant proportion of shoulder pathologies. With progress in imaging techniques, the pre-operative detection and characterisation of rotator cuff injuries has become much easier. Ultrasound (USG) and Magnetic Resonance Imaging (MRI) are the most commonly used imaging modalities for rotator cuff tears. Excellent soft tissue resolution, multiplanar imaging and non-invasive technique have made MRI the imaging modality of choice in evaluation of rotator cuff. However, high cost and limited availability prevent it from becoming the screening modality of choice. USG on the other hand is cheap and easily available and hence can be made the first modality for rotator cuff tears.

Aim: To determine the efficacy of USG in detecting rotator cuff tears in comparison to MRI.

Materials and Methods: We evaluated 50 patients of all age groups in Department of Radiology, Gauhati Medical College and Hospital, Assam, India, with suspicious rotator

cuff tears first by high resolution USG and then by 1.5 T MRI. Both USG and MRI were performed by the same radiologist. Since MRI was always followed by USG, the radiologist was blind to the MRI results.

Results: Supraspinatus was the most commonly affected tendon (79%). Partial thickness tears were the most common rotator cuff pathology. USG showed a sensitivity of 66.67%, specificity of 92.5%, PPV of 68.96% and NPV of 91.74% in detecting partial thickness tears. Whereas, USG showed excellent results in detecting full thickness tears with a sensitivity of 100%, specificity of 99.31%, PPV of 91.74% and NPV of 100%.

Conclusion: USG done has a near similar accuracy for detecting full thickness rotator cuff tears as MRI and has an acceptable accuracy for detecting partial thickness tears too. Hence, due to its availability, accuracy and cost effectiveness, USG should be made the first line modality for detecting rotator cuff tears and MRI should be reserved for indeterminate or complex cases where USG does not suffice in serving the clinical purpose.

Keywords: High resolution USG, MRI shoulder, Musculoskeletal imaging

INTRODUCTION

Shoulder pain is one of the most common presentations in Orthopaedic patients after low back pain and knee pain. It is associated with significant morbidity and disability. The functional limitations resulting due to shoulder disability increase with age [1,2].

Rotator cuff pathologies consist of a significant proportion of shoulder pathologies. Ranging from tendinosis to complete tears, a variety of rotator cuff pathologies can result in significant functional limitation [3].

The rotator cuff consists of four muscles viz supraspinatus, infraspinatus, subscapularis and teres minor which primarily have the function of supporting the humeral head. These muscles originate from the scapula and their tendons insert in both tuberosities of humerus. Imaging of rotator cuff

focuses on assessing the integrity of the tendons of these four muscles [3].

Even though shoulder impingement is a clinical diagnosis, the role of imaging lies in evaluating the cause of impingement and the rotator cuff tendons. The knowledge of integrity of rotator cuff tendons along with the type and extent of tears plays a major role in shaping the therapeutic approach [4].

A variety of diagnostic modalities have been used by the clinicians over time for diagnosing rotator cuff pathologies. Arthrography, a highly invasive procedure, was traditionally used pertaining to its accurate detection of complete tears. However, after the advent of USG and MRI which are non-invasive and highly accurate, its role is now limited to indeterminate cases [5].

High resolution USG has gained popularity as a simple, fast, non-invasive and accurate imaging modality in evaluation of rotator cuff pathologies. The benefit of real time dynamic imaging which can be done in multiple planes is an additive benefit of USG. Along with accurate detection of size and extent of rotator cuff tears, USG can also detect other abnormalities that may mimic rotator cuff tears like tendinosis, calcific tendinitis, greater tuberosity fracture and adhesive capsulitis. Interobserver variation especially in case of partial thickness tears, along with its limited usefulness in obese patients and patients with severe movement restriction are its main limitation [6-8].

MRI is now the preferred modality for diagnosis of rotator cuff tears. Its primary advantage is its superior soft tissue resolution along with other benefits of non-invasive technique and multiplanar approach. Multiple assessment criteria are well accomplished by MRI evaluation such as dimension, size and extent of the tear along with secondary changes such as tendon retraction and degree of muscle atrophy. Therefore, MRI is extremely helpful aid to both radiologist and surgeon in planning the therapeutic approach [9].

However, high cost, limited availability and long examination times are its major disadvantages. MRI also has limited usage in claustrophobic patients and patients with implants such as pacemakers [10].

Thus, even though more accurate than USG, MRI cannot become the screening modality of choice for rotator cuff pathologies in a country like India where cost and availability are major patient concerns.

The present study aims at evaluating the efficacy of role of USG in detecting rotator cuff tears in comparison to MRI, which we have taken as Gold standard.

MATERIALS AND METHODS

After obtaining due approval from institutional ethical committee, a prospective study was done at the Department of Radio-Diagnosis, Gauhati Medical College and Hospital, Guwahati, Assam for 18 months from April 2013 to October 2014.

Patient selection: The study comprised of 50 patients of all age groups with the inclusion criteria being patients with clinically suspected rotator cuff injuries. We excluded the patients with history of claustrophobia and Patients with

metallic prosthetic implants from our study. Patients with previous surgical history were also excluded from the study. A detailed clinical history was taken followed by USG and MRI evaluation.

Each patient was first taken up for USG which was followed by MRI evaluation; thus making the radiologist blind to MRI results. Both USG and MRI were conducted by the same radiologist.

Ultrasound examination of the shoulder: The examination on the affected shoulder was carried out on SIEMENS Acuson Antares machine, with a high frequency linear transducer VFX13-5 which has a frequency range of 5-13 MHz. The long head of biceps was used as the landmark and thereafter sequential scanning of subscapularis, supraspinatus followed by scanning of infraspinatus and teres minor were performed in both long and short axes (both axial and sagittal planes). The acromio clavicular joint and the posterior aspect of the shoulder joint were also examined. Comparison with the opposite shoulder was also done.

MRI of the affected shoulder: Plain MRI was performed on 1.5 Tesla SIEMENS Avanto machine using shoulder coil. Patient was positioned supine and was asked to have a neutral shoulder position. A sponge was placed at the elbow and another one supporting the hand and the arm was strapped in place to prevent movement. The protocol for MRI is depicted in [Table/Fig-1].

Assessment

Criteria for Rotator Cuff Tear on USG [11]

Following criteria were followed in our study for diagnosing rotator cuff tears:

- Full thickness tear:**
1. A total non-visualization of the cuff.
 2. Focal non-visualization of tendon which is confirmed on at least two planes.

Partial thickness tear: can be classified into articular surface, intrasubstance and bursal surface tears.

1. A focal area of hypoechogenicity or heteroechogenicity extending to either articular or bursal surface of tendon.
2. Flattening at the bursal side of the cuff.
3. Intratendinous fluid filled line without exiting at bursal or articular surfaces was diagnosed as intrasubstance tears.

Sequence No.	1	2	3	4	5	6	7
Sequence Type	T2 Medic	PD FS	T2 TSE	PD FS	T1 TSE	T2 TSE	PD FS
Orientation	Axial	Axial	Coronal Oblique	Coronal Oblique	Coronal Oblique	Sagittal Oblique	Sagittal Oblique
Field View (cm)	16-18	16-18	16-18	16-18	16-18	16-18	16-18
Slice Thickness (mm)	3	3	3	3	3	3	3

[Table/Fig-1]: Protocol for MRI evaluation of shoulder for rotator cuff injuries.

Criteria of Tendinosis on USG

1. Thickened or hypoechoic tendon.
2. Effacement of fibrillar pattern.

Supportive (Indirect) criteria for rotator cuff tear: highly suggestive of rotator cuff tear-

1. Fluid in the subacromial-subdeltoid bursa.
2. Fluid along the biceps tendon sheath.
3. Irregularity of the greater tuberosity.

Criteria of Rotator Cuff Tears on MRI [6,12]

Full thickness tear: A hyperintense defect on T2W images or a tendinous avulsion that extends from the bursal to the articular side of the cuff.

Partial thickness tear: Focal area of hyperintensity which extends to one surface only, either articular or bursal; or is within the tendon itself.

Criteria of Tendinosis on MRI

Intrasubstance hyperintense area on PDFS images which is not hyperintense on T2W images.

Criteria for Rupture and Dislocation [13]

Bicipital tendon is often affected in tandem with a rotator cuff injury. A possible tendinosis, subluxation, dislocation, partial tear or rupture may be seen in the bicipital tendon.

The criteria for diagnosing a rupture on USG were taken as the absence of the bicipital tendon in the bicipital groove.

In MRI, T2 hyperintense fluid signal was seen in the groove in absence of the tendon.

While, in case of dislocation, the tendon moves outside and medial to the bicipital groove on both USG and MRI.

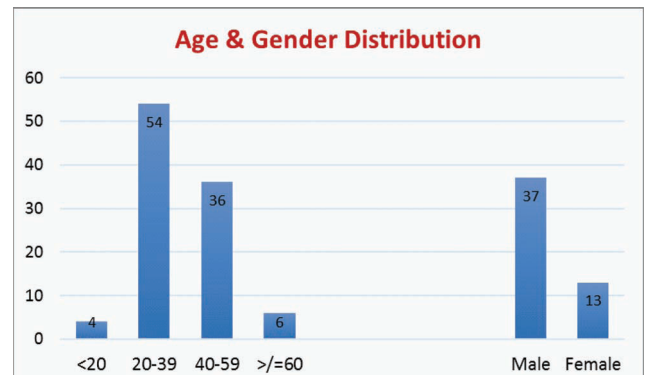
STATISTICAL ANALYSIS

Descriptive statistical analysis was carried out. Results of continuous measurements were presented on mean and results of categorical measurements are presented in number (%). Sensitivity, specificity, positive predictive value, negative predictive value and accuracy were computed for various parameters. Cohen's kappa coefficient was used to determine inter modality agreement between two variables. All calculations have been done using the statistical software namely SAS 9.2, SPSS 15.0 and Microsoft Excel.

RESULTS

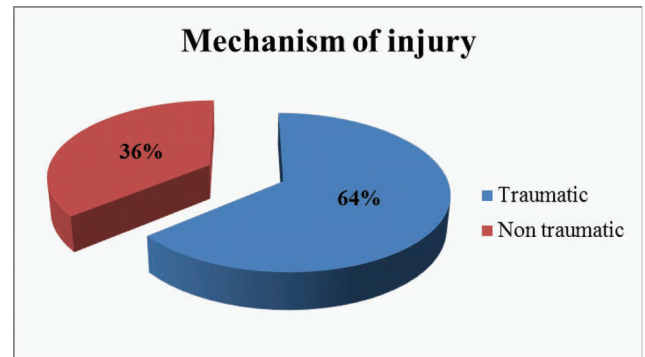
Demographics: Our study group consisted of 50 patients from 18 to 67 years age. Mean age of presentation was 37.1 years. Maximum patients were between 20-39 years (54). Most patients in our study group (37 patients: 74%) were males [Table/Fig-2].

Clinical presentation: Pain in the shoulder was the most common cause of presentation universally present in all



[Table/Fig-2]: Demographic profile of the study group.

patients of the study group. Total 36 patients (72%) showed movement restriction in the affected shoulder. Traumatic injury was the most common causal factor seen in 32 (64%) patients of the study group [Table/Fig-3].



[Table/Fig-3]: Mechanism of injury.

Twenty patients (40%) presented in a time frame of 1-6 months after injury while 18 (36%) presented more than one year after injury. Only six patients i.e., 12% presented within one month of trauma.

Right shoulder was predominantly affected in 41 (82%) patients, out of which for 40 patients it was the dominant hand.

Out of the 50 cases in the study group, MRI showed rotator cuff pathology in 44 cases (88%) while USG showed in 40 cases (80%).

Individual tendon affection: Amongst the rotator cuff tendons, Supraspinatus tendon affection was most common with 39 cases (78%) showing abnormality on USG and 40 cases (80%) on MRI. Subscapularis was the next most commonly affected with 15 cases showing abnormal findings on both USG and MRI. Infraspinatus tendon showed abnormality in two cases (4%) on USG and four cases (8%) on MRI. Teres minor was normal in all the patients.

Ultrasound and MRI evaluation: The imaging results were labeled as full thickness tear, partial thickness tear and tendinosis.

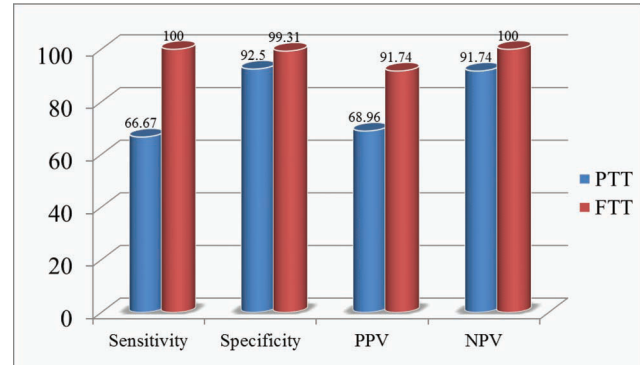
On USG evaluation, of the 39 cases which showed pathology in supraspinatus, 24 cases showed partial thickness tears, five cases showed full thickness tears and the rest 10 cases showed tendinosis. MRI detected supraspinatus pathology in 40 patients out of which there was partial thickness tear in 25 patients and full thickness tear in four patients while the rest 11 were tendinosis. Whereas, USG was able to correctly detect partial supraspinatus tendon tears in 18 of these 25 cases. While out of the rest of the seven cases, five were falsely shown to be tendinosis, one was shown as full thickness tear and one as normal on USG.

In six cases USG falsely diagnosed partial-thickness tear of the supraspinatus tendon out of which four cases were found to be of tendinosis and two cases were normal on MRI.

MRI showed full thickness tears of the supraspinatus in four cases all of which were correctly diagnosed by USG.

Both USG and MRI showed subscapularis pathology in 15 cases. However, USG showed partial thickness tear of the subscapularis in six patients and tendinosis in nine patients while on MRI evaluation only four patients were shown to have partial thickness tears in the subscapularis and the rest 11 were designated as tendinosis. No patient was found to have a full thickness tear in the subscapularis tendon.

USG showed one partial thickness and one full thickness tear in Infraspinatus while MRI detected two cases of partial thickness tears, one case of full thickness tear and tendinosis each in the Infraspinatus [Table/Fig-4].



[Table/Fig-4]: Results of USG and MRI in detecting rotator cuff tears.

The comprehensive evaluation of performance of USG for evaluating both partial thickness tears and full thickness tears, in terms of statistical analysis are presented in [Table/Fig-5].

Kappa value depicting inter-modality agreement for both modalities was found to be 0.59 (moderate agreement) for partial thickness tears and 0.91 for full thickness tears (almost perfect agreement).

Findings		Sensitivity	Specificity	PPV	NPV	Accuracy	Kappa value
Partial Thickness Tear	Subscapularis	75.00	93.48	50.00	97.73	92.00	0.558
	Supraspinatus	72	76	75	73.08	74.00	0.480
	Infraspinatus	50.00	100	100	95.83	96.00	0.658
Full Thickness Tear	Subscapularis	0.00	100	0.00	100	100	NA
	Supraspinatus	100	97.83	80.00	100	98.00	0.878
	Infraspinatus	100	100	100	100	100	1.000
Tendinosis	Subscapularis	54.55	92.31	66.67	87.80	84.00	0.501
	Supraspinatus	27.27	82.05	30.00	80.00	70.00	0.096
	Infraspinatus	0.00	100	0.00	98.00	98.00	0.000

[Table/Fig-5]: Tendon wise analysis of USG and MRI results.

Findings		No. of cases	Sensitivity (USG)	Specificity (USG)	PPV (USG)	NPV (USG)
Sub-Acromial Sub-Deltoid fluid	USG	26	86.67%	100%	100%	83.33%
	MRI	30				
Sub-Coracoid Bursal Fluid	USG	0	-	-	-	-
	MRI	13				
Peri-Bicipital Tendon Fluid	USG	17	58.62%	100%	100%	63.64%
	MRI	29				
Acromio-Clavicular Joint Arthrosis	USG	11	37.93%	100%	100%	53.85%
	MRI	29				

[Table/Fig-6]: Statistical results of associated findings as depicted by USG.

Subacromial-Sub Deltoid (SASD) bursal fluid was the most common associated finding. USG showed a high sensitivity in detecting SASD bursal fluid. While in detecting other associated findings such as sub-coracoid bursal fluid and peri-bicipital tendon fluid USG showed a significantly lower sensitivity [Table/Fig-6].

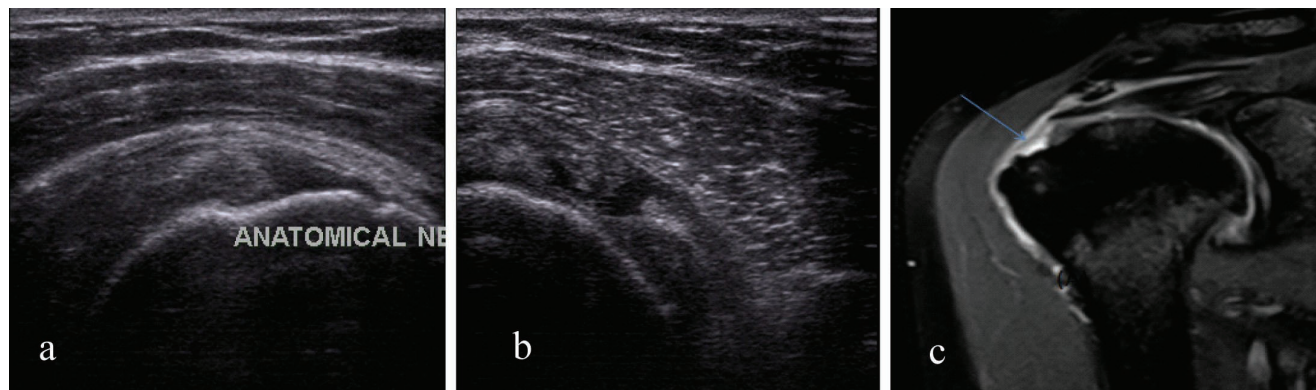
DISCUSSION

Shoulder pain being one of the commonest causes of musculoskeletal pain warrants accurate diagnostic results. The integrity of rotator cuff is the most common question put forward by the clinician to the radiologist. Even though MRI is already established to be a highly accurate imaging modality in rotator cuff pathologies, it is essential to demark the efficacy of USG in a developing country like India where cost and availability are major limitations of MRI.

Out of the 50 patients we evaluated, most number of patients were young presenting in the 20-39 years (54%) age group. This was in coordination with the study of Worland et al., [14]. We found a definitive male to female predominance of 2.84:1 in our study.

Right shoulder was affected in 41 (82%) of our cases, while the left side was affected in only 9 (18%) of our patients. Right shoulder was dominant in 40 (80%) of our cases, while the left side was dominant in 10 (20%) of our patients. Similar findings were observed by Patidar et al., in their study [15].

It is known that tears of the rotator cuff tendons may occur as a result of trauma solitarily or age related tendon degeneration but more often a combination of these factors causes a resultant cuff tear. Rotator cuff tendon degeneration and accidental falls are both known to increase in incidence with increasing age. In our study, the majority, 53.3%, reported a fall associated with their rotator cuff tear. The tears nearly always occurred on the same side as the fall thereby highlighting that trauma is the leading cause of injury in the rotator cuff. These findings are in concordance with the study of Lungren et al., [16].



[Table/Fig-8a-c]: A 50 year old patient with three months of shoulder pain. (a&b) USG shows hypoechoic defect extending from articular surface to bursal surface of supraspinatus with SASD bursal fluid; (c) Coronal oblique PDFS image shows hyperintensity within the supraspinatus tendon.

Study	Partial Thickness Tears		Full Thickness Tears	
	Sensitivity	Specificity	Sensitivity	Specificity
Present Study	66.67%	92.50 %	100%	99.51%
Roy JS et al., [6]	68%	94%	91%	93%

[Table/Fig-7]: Final comparison of study results with meta-analysis of Roy JS et al.

In our study, supraspinatus was the most commonly affected tendon with 39 cases (78%) showing abnormality on USG and 40 cases (80%) on MRI. Concordant to our study, studies done by Iagnocco et al., [17] and Naredo et al., [18] have also demonstrated supraspinatus to be the most commonly involved tendon and teres minor least commonly involved.

Supraspinatus is found to be this commonly involved in various studies because it is located between the head of humerus and acromion and hence the tendon is easily compressed during shoulder movement which on long term basis may result in ischaemic changes and later degenerative features.

Partial thickness tears were found to be more common than full thickness tears in the present study. This correlated with the studies of Brenneke et al., [19].

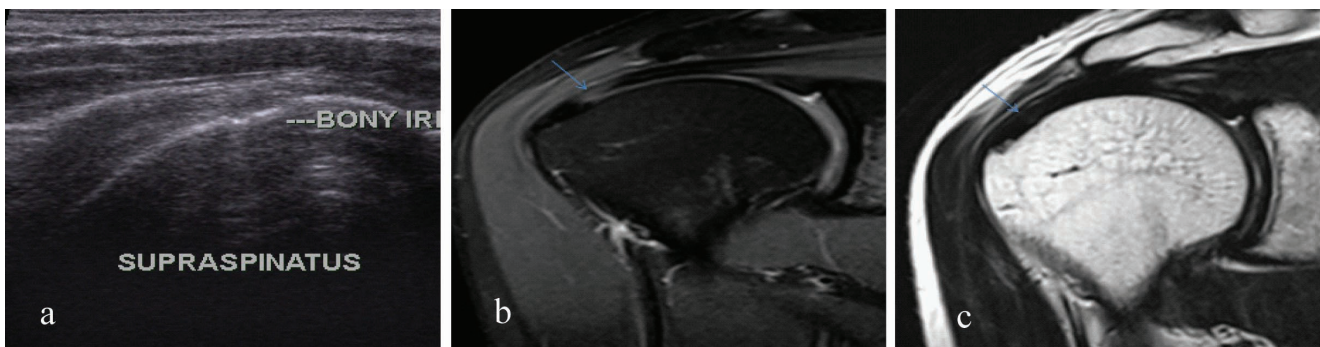
An individual tendon wise analysis for rotator cuff pathology is presented in [Table/Fig-5].

The results of our study were in correspondence to the meta-analysis done by Roy JS et al., [Table/Fig-7] [6], who observed that USG showed a sensitivity of 91% and specificity of 93 % for full thickness tears and a sensitivity of 68 % and specificity of 94% for partial thickness tears.

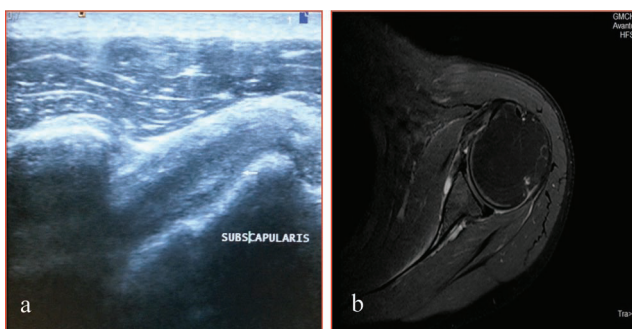
Apart for a lower accuracy of USG in detecting partial thickness tears, other interpretations of our study are similar to the study of Rutten et al., [20].

The spectrums of imaging findings seen in the study are depicted in [Table/Fig 8-12].

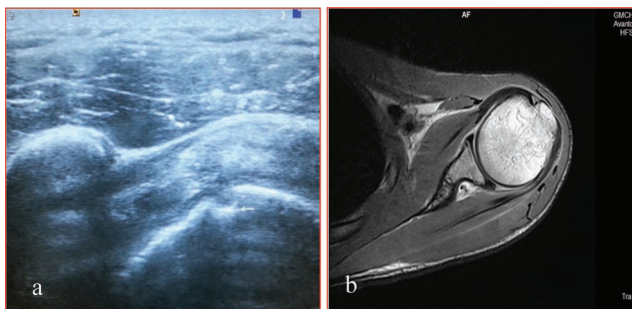
Associated findings: SASD bursal fluid was found in 30 (60%) of the 50 patients with suspected rotator cuff injury. All these



[Table/Fig-9a-c]: USG shows bony irregularity with adjacent hypoechoic partial thickness articular side defect in Supraspinatus. MRI PDFS and T2 coronal oblique images, show area of increased signal in the distal supraspinatus tendon with mild thickening of tendon, however no e/o fluid signal noted, findings suggestive of tendinosis.



[Table/Fig-10a,b]: (a) Subscapularis Tendinosis: Longitudinal view of subscapularis tendon on USG, showing diffusely enlarged and hypoechoic tendon; (b) MRI axial PDFS image, showing diffuse enlargement and edema of tendon. Findings consistent with tendinosis.

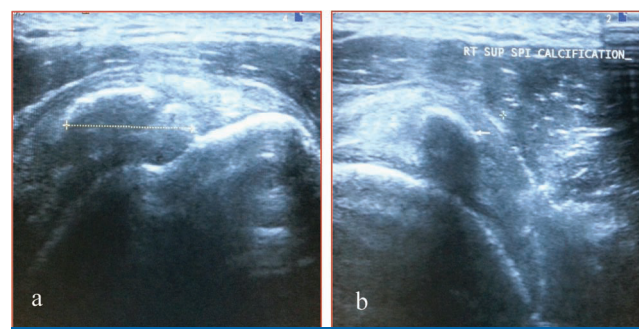


[Table/Fig-11a,b]: (a) Ultrasound longitudinal view of subscapularis tendon, showing hypoechoic partial thickness subscapularis tendon tear with cortical irregularity at its insertion site; (b) MRI axial PDFS image, showing normal subscapularis tendon.

patients had supraspinatus tendon involvement; this finding was in accordance with the study done by Hollister et al., [21].

Tendon sheath effusion along the biceps tendon was the second most common imaging finding in association with the rotator cuff tears. This was pertaining to the synovial sheath of the biceps is an extension of the glenohumeral synovial membrane.

In a full thickness tear, both bursal and joint fluid is resultant of a direct communication formed by the defect whereas in a



[Table/Fig-12a,b]: Supraspinatus calcific tendinitis. (a and b) Ultrasound longitudinal and transverse views of supraspinatus tendon respectively.

partial thickness tear is due to the mechanical irritation of the bursa by the partially injured cuff. In full-thickness tears, the volume of fluid within the bursa is far greater than that seen in partial-thickness tears or impingement.

Acromioclavicular joint abnormalities were found in 29(58%) of the 50 patients with suspected rotator cuff injury. Twenty five of them had supraspinatus tendon involvement, which is in accordance with the study done by Iagnocco et al., [17].

Our study is significant in today's perspective as it analyses the role of USG which is cheap and easily available in our country as against MRI which still has limited availability and has cost constraints. Therefore, analysing the efficacy of a modality that has a more wide spread demographic coverage is essential so that it is known to clinicians that in absence of MRI, USG can also help direct the further course of management in a suspected rotator cuff injury patient.

LIMITATION

Even though MRI is known to be a highly accurate imaging modality for rotator cuff tears, the Gold Standard for the same remains arthrography which in recent years has changes to MR arthrography. At our institution, we could not perform MR arthrography and hence could not compare our results with it.

CONCLUSION

With progress in imaging techniques, the detection and characterisation of rotator cuff injuries has become much easier now. As per our study, USG done by properly trained professionals has a near similar accuracy for detecting full thickness rotator cuff tears as MRI and has an acceptable accuracy for detecting partial thickness tears too. It is thereby concluded that due to its availability, accuracy and cost effectiveness, USG should be made the first line modality for detecting rotator cuff tears and MRI should be reserved for indeterminate or complex cases where USG does not suffice in serving the clinical purpose.

REFERENCES

- [1] Urwin M, Symmons D, Allison T, Brammah T, Busby H, Roxby M, et al. Estimating the burden of musculoskeletal disorders in the community: the comparative prevalence of symptoms at different anatomical sites, and the relation to social deprivation. *Annals of the Rheumatic Diseases*. 1998;57(11):649-55.
- [2] Woolf AD, Pfleger B. Burden of major musculoskeletal conditions. *Bulletin of the World Health Organization*. 2003;81(9):646-56.
- [3] Bianchi S, Martinoli C. Shoulder. In: *Ultrasound of the musculoskeletal system*. Springer Berlin Heidelberg. 2007. Pages-189-331.
- [4] Blanchard TK, Bearcroft PW, Constant CR, Griffin DR, Dixon AK. Diagnostic and therapeutic impact of MRI and arthrography in the investigation of full-thickness rotator cuff tears. *European radiology*. 1999;9(4):638-42.
- [5] de Jesus JO, Parker L, Frangos AJ, Nazarian LN. Accuracy of MRI, MR arthrography, and ultrasound in the diagnosis of rotator cuff tears: a meta-analysis. *American Journal of Roentgenology*. 2009;192(6):1701-07.
- [6] Roy JS, Brañ C, Leblond J, Desmeules F, Dionne CE, MacDermid JC, et al. Diagnostic accuracy of ultrasonography, MRI and MR arthrography in the characterisation of rotator cuff disorders: a systematic review and meta-analysis. *British journal of sports medicine*. 2015;49(20):1316-28.
- [7] Moosikasuwan JB, Miller TT, Burke BJ. Rotator cuff tears: clinical, radiographic, and US findings. *Radiographics*. 2005;25(6):1591-607.
- [8] Patil P, Dasgupta B. Role of diagnostic ultrasound in the assessment of musculoskeletal diseases. *Therapeutic advances in musculoskeletal disease*. 2012;4(5):341-55.
- [9] Morag Y, Jacobson JA, Miller B, De Maeseneer M, Girish G, Jamadar D. MR imaging of rotator cuff injury: what the clinician needs to know. *Radiographics*. 2006;26(4):1045-65.
- [10] Dean Deyle G. The role of MRI in musculoskeletal practice: a clinical perspective. *Journal of Manual & Manipulative Therapy*. 2011;19(3):152-61.
- [11] Chaubal NG. Ultrasonography of shoulder (rotator cuff). *Indian Journal of Radiology and Imaging*. 2007;17(3):209.
- [12] Zlatkin MB. Rotator Cuff Disease. In: Zlatkin MB. *MRI of the shoulder*. 2nd Ed. Philadelphia: Lippincott Williams & Wilkins; 2003.
- [13] Fischer CA, Weber MA, Neubecker C, Bruckner T, Tanner M, Zeifang F. Ultrasound vs. MRI in the assessment of rotator cuff structure prior to shoulder arthroplasty. *Journal of Orthopaedics*. 2015;12(1):23-30.
- [14] Worland RL, Jessup DE, Arredondo J, Warburton KJ. Bipolar shoulder arthroplasty for rotator cuff arthropathy. *Journal of Shoulder and Elbow Surgery*. 1997;6(6):512-15.
- [15] Patidar M, Patil A, Verma V, Kaushal L. Evaluation of painful shoulder with high frequency sonography and their comparison with the clinical diagnosis made by physical examination. *Nepalese Journal of Radiology*. 2013;2(2):43-50.
- [16] Lungren MP, Smith D, Carpenter JE, Hughes RE. Fall-related rotator cuff tears. *Journal of Musculoskeletal Research*. 2006;10(02):75-81.
- [17] Iagnocco A, Coari G, Leone A, Valesini G. Sonographic study of painful shoulder. *Clinical and Experimental Rheumatology*. 2003;21(3):355-58.
- [18] Naredo E, Iagnocco A, Valesini G, Uson J, Beneyto P, Crespo M. Ultrasonographic study of painful shoulder. *Annals of the rheumatic diseases*. 2003;62(10):1026-27.
- [19] Brenneke SL, Morgan CJ. Evaluation of ultrasonography as a diagnostic technique in the assessment of rotator cuff tendon tears. *The American Journal of Sports Medicine*. 1992;20(3):287-89.
- [20] Rutten MJ, Spaargaren GJ, van Loon T, de Waal Malefijt MC, Kiemeny LA, Jager GJ. Detection of rotator cuff tears: the value of MRI following ultrasound. *European radiology*. 2010;20(2):450-57.
- [21] Hollister MS, Mack LA, Patten RM, Winter 3rd TC, Matsen 3rd FA, Veith RR. Association of sonographically detected subacromial/subdeltoid bursal effusion and intraarticular fluid with rotator cuff tear. *American Journal of Roentgenology*. 1995;165(3):605-08.

AUTHOR(S):

1. Dr. Vishal Dhirenghai Thakker
2. Dr. Dipu Bhuyan
3. Dr. Manali Arora
4. Dr. Mohsina Islam Bora

PARTICULARS OF CONTRIBUTORS:

1. Senior Resident, Department of Radio-Diagnosis, Pramukhswami Medical College, Anand, Gujarat, India.
2. Associate Professor, Department of Radio-Diagnosis, Gauhati Medical College and Hospital, Guwahati, Assam, India.
3. Senior Resident, Department of Radio-Diagnosis, Pramukhswami Medical College, Anand, Gujarat, India.

4. Registrar, Department of Radio-Diagnosis, Gauhati Medical College and Hospital, Guwahati, Assam, India.

NAME, ADDRESS, E-MAIL ID OF THE CORRESPONDING AUTHOR:

Dr. Vishal Dhirenghai Thakker,
House No. 1546, Sector 15, Sonapat-131009,
Haryana, India.
E-mail: docvdt@gmail.com

FINANCIAL OR OTHER COMPETING INTERESTS:

None.

Date of Publishing: Jul 01, 2017